

Case report

Open Access

Haematuria as a presentation of metastatic oesophageal carcinoma

R Hargunani, S Al-Dujaily*, AKS Abdulla and DR Osborne

Address: Department of Urology, Basildon University Hospital, Essex, UK

Email: R Hargunani - rikin@doctors.org.uk; S Al-Dujaily* - Saad.Al-dujaily@btuh.nhs.uk; AKS Abdulla - Abdel.Abdulla@btuh.nhs.uk; DR Osborne - David.Osborne@btuh.nhs.uk

* Corresponding author

Published: 20 February 2005

Received: 11 January 2005

Accepted: 20 February 2005

International Seminars in Surgical Oncology 2005, **2**:4 doi:10.1186/1477-7800-2-4

This article is available from: <http://www.issoonline.com/content/2/1/4>

© 2005 Hargunani et al; licensee BioMed Central Ltd.

This is an Open Access article distributed under the terms of the Creative Commons Attribution License (<http://creativecommons.org/licenses/by/2.0>), which permits unrestricted use, distribution, and reproduction in any medium, provided the original work is properly cited.

Abstract

Haematuria is a classical symptom of urological disease often signifying a primary bladder cancer. Rarely, however, the presence of blood in the urine can be due to secondary spread of tumours into the bladder from distant sites. Notably this has been reported to occur in breast cancer, malignant melanoma and gastric cancers. Haematuria due to spread from a primary oesophageal cancer to the bladder has never been reported. We present a case of haematuria confirmed histologically to be due to metastases from a primary oesophageal tumour. Oesophageal cancer is capable of spread to all three neighbouring compartments (abdomen, chest and neck) and therefore has the potential to spread to unusual sites. Clinicians should always carefully regard haematuria in a patient previously treated for cancer and retain a high index of suspicion for distant metastases as being the cause.

Background

Haematuria is a commonly encountered symptom. It often represents the presence of serious disease such as a malignancy within the bladder. The majority of bladder tumours tend to be primary, and histologically these are usually transitional cell carcinomas. We present a case of haematuria which occurred due to metastases from a primary oesophageal carcinoma diagnosed 2 years prior and treated curatively.

Case presentation

A 45-year old male presented to our unit with acute onset macroscopic haematuria. His past medical history was significant in that he had been diagnosed with adenocarcinoma of the distal oesophagus 2 years prior and had undergone curative resection after neo-adjuvant chemotherapy. At that time the tumour was found to be poorly differentiated with evidence of local nodal spread. He had

been reviewed regularly by the oncologists and remained asymptomatic until the onset of frank haematuria.

He subsequently underwent cystoscopy, which revealed a solid bladder tumour on the right lateral wall, which was treated with trans-urethral resection. Pathological examination confirmed a poorly differentiated mucus-secreting adenocarcinoma, identical histologically to the original oesophageal tumour (Figures 1 and 2).

A diagnosis of metastatic oesophageal adenocarcinoma to the bladder was made. A CT scan did not demonstrate any pelvic tumour outside the bladder and therefore metastasis by the trans-coelomic route was essentially excluded, indicating haematogenous spread of the primary oesophageal carcinoma. The patient was referred for further oncological therapy but unfortunately died 4 months later from disseminated carcinoma.

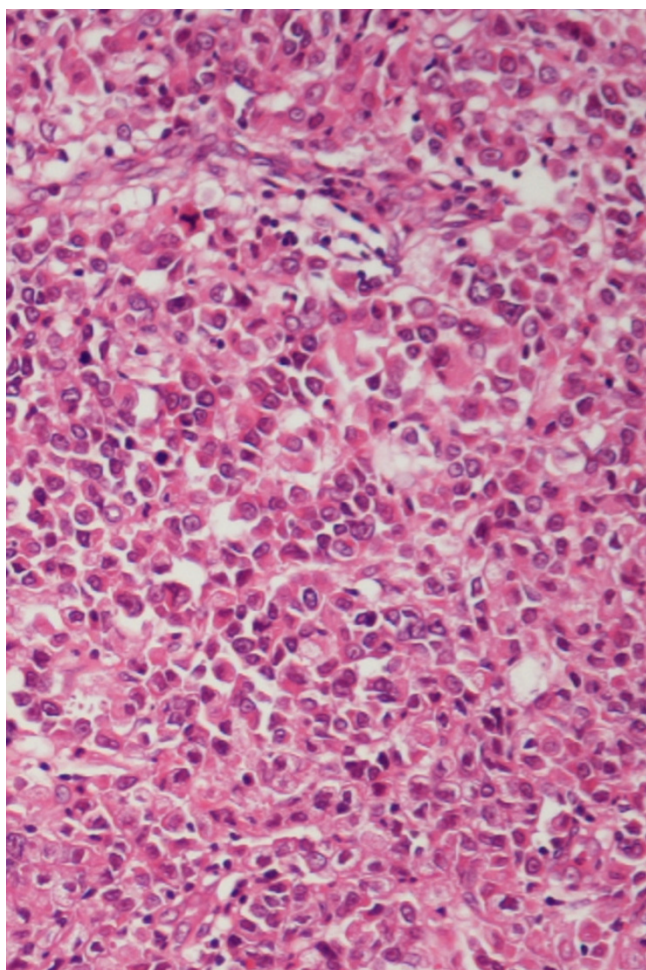


Figure 1
Original oesophageal adenocarcinoma (H & E stain).

Discussion

Metastatic tumour spread to the bladder constitutes approximately 2% of all bladder neoplasms [1]. Gross haematuria occurs relatively infrequently in secondary tumours of the bladder as most lesions are small and infiltrate the bladder wall without causing ulceration of the mucosa [2]. Therefore most metastases to the bladder remain asymptomatic and often undiagnosed.

The bladder can be the recipient of metastatic tumour spread from a potentially large variety of primary sites. Most commonly direct invasion can occur from adjacent tumours of the lower gastrointestinal tract (33% of secondary neoplasms), prostate (19%) and female genital tract (11%) [1]. Less commonly, distant metastases have been described, notably from the stomach, skin, breast and lung in descending order of frequency [2-5]. The

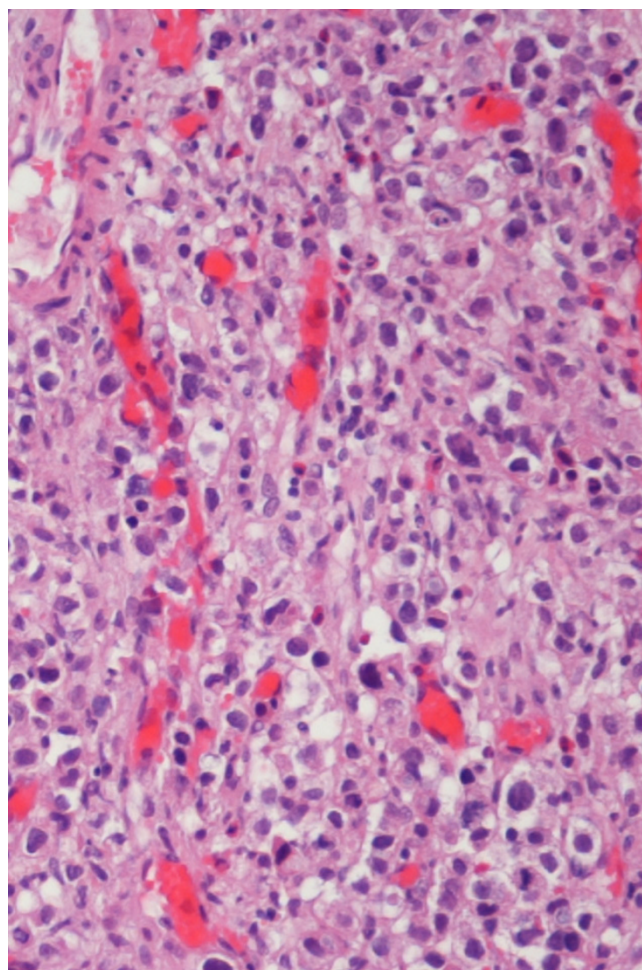


Figure 2
Metastatic tumour to the bladder (H & E stain). Both light micrographs demonstrate extensive infiltration by a poorly differentiated adenocarcinoma with the same histopathological features.

management and prognosis of such tumours can differ significantly from that of primary bladder tumours since they are often indicative of late disease.

Despite curative intent, surgical resection of oesophageal adenocarcinoma is associated with an overall tumour recurrence rate of 66% at 5 years [6]. The lymphatic drainage of the oesophagus is longitudinal via the submucosal plexus and not segmental. As a consequence lymph node metastases can occur relatively early in all three compartments (abdomen, chest and neck) regardless of the location of the primary tumour [7].

In autopsy studies, isolated lymph node metastases were found in approximately one half of patients with end-

stage oesophageal carcinoma, with a similar proportion having combined lymph node and visceral metastases. Isolated visceral spread however is rare, accounting for only a handful of cases of primary oesophageal tumour spread [8].

Notable sites of haematogenous dissemination of primary oesophageal carcinoma to distant organs include bone, liver, skin, lungs, adrenals, brain and peritoneum in descending order of frequency [6]. A few authors, most notably in Japan, have described cases of oesophageal cancers metastasising to the kidney. These cases may present with haematuria but often are associated with flank pain [9-14].

Interestingly, rare synchronous primary tumours of the bladder and oesophagus have been described [15,16] but haematuria due to secondary spread of oesophageal cancer has never previously been reported.

Conclusion

Haematuria may be the only clinically apparent symptom of metastatic tumour spread to the bladder from a potentially large number of primary sites and therefore should be considered by all clinicians irrespective of specialty.

Competing interests

The author(s) declare that they have no competing interests.

Acknowledgements

Written consent was obtained from the patient's relatives for publication of study.

References

- Bates AW, Baithun SI: **Secondary neoplasms of the bladder are histological mimics of nontransitional cell primary tumours: clinico-pathological and histological features of 282 cases.** *Histopathology* 2000, **36**:32-40.
- Ganem EJ, Batal JT: **Secondary malignant tumours of the urinary bladder metastatic from primary foci in distant organs.** *J Urol* 1956, **75**:965-972.
- Fink W, Zimpfer A, Ugurel S: **Mucosal metastases in malignant melanoma.** *Onkologie* 2003, **26**:249-251.
- Menendez Lopez V, Alvarez-Vijande Garcia R, Sole Arques M, Carretero Gonzalez P: **Bladder metastasis of malignant melanoma: report of a case.** *Arch Esp Urol* 2002, **55**:1277-1279.
- Soon PS, Lynch VV, Schwartz P: **Breast cancer presenting initially with urinary incontinence: a case of bladder metastasis from breast cancer.** *Breast* 2004, **13**:69-71.
- van Lanschot JJB, Tilanus HW, Voormolen HJ, van Deelan RAJ: **Recurrence pattern of oesophageal carcinoma after limited resection does not support wide local excision with extensive lymph node dissection.** *Br J Surg* 1994, **81**:1320-1323.
- Hulscher JB, van Sandick JVV, Tijssen JG, Obertop H, van Lanschot JJ: **The recurrence pattern of esophageal carcinoma after transhiatal resection.** *J Am Coll Surg* 2000, **191**:143-148.
- Sons HU, Borchard F: **Cancer of the distal esophagus and cardia. Incidence, tumorous infiltration and metastatic spread.** *Ann Surg* 1986, **203**:188-195.
- Nagai T, Takashi M, Sakata T, Sahashi M, Simoji T, Miyake K: **A case of esophageal cancer metastatic to the kidney presenting as renal pelvic cancer.** *Hinyokika Kyo* 1989, **35**:1565-1568.
- Miyoshi Y, Asakura T, Matsuzaki J, Fukuda M, Satomi Y: **Metastatic renal tumor originating from esophageal cancer: report of 2 cases.** *Hinyokika Kyo* 1997, **43**:347-350.
- Grise P, Botto H, Camey M: **Esophageal cancer metastatic to kidney: report of 2 cases.** *J Urol* 1987, **137**:274-276.
- Marsan RE, Baker DA, Morin ME: **Esophageal carcinoma presenting as a primary renal tumor.** *J Urol* 1979, **121**:90-91.
- Mikata N, Imao S, Katoh A, Matsuo S: **Esophageal cancer metastatic to the kidney: report of a case.** *Nippon Gan Chiryo Gakkai Shi* 1990, **25**:1492-1496.
- Hayashida H, Konishi T, Pak K, Tomoyoshi T: **Metastatic renal tumor from esophageal carcinoma.** *Hinyokika Kyo* 1987, **33**:69-73.
- Tamura K, Inoue K, Fukata S, Kamada M, Shuin T: **Small cell carcinoma of the urinary bladder with synchronous esophageal cancer and incidental lung cancer: a case report.** *Hinyokika Kyo* 2001, **47**:273-276.
- Takai K, Moriyama N, Shinohara M, Fukutani K, Mikata N, Yokoyama M, Kogure T: **Synchronous double cancer of the esophagus and the urinary bladder: report of two cases.** *Hinyokika Kyo* 1983, **29**:1085-1089.

Publish with **BioMed Central** and every scientist can read your work free of charge

"BioMed Central will be the most significant development for disseminating the results of biomedical research in our lifetime."

Sir Paul Nurse, Cancer Research UK

Your research papers will be:

- available free of charge to the entire biomedical community
- peer reviewed and published immediately upon acceptance
- cited in PubMed and archived on PubMed Central
- yours — you keep the copyright

Submit your manuscript here:
http://www.biomedcentral.com/info/publishing_adv.asp

