

Case report

Open Access

## Recurrence of granulosa cell tumour after thirty years with small bowel obstruction

Gurpreet Singh-Ranger\*, Andrew Sharp and James N Crinnion

Address: Department of General Surgery c/o Wavell Ward Whipps Cross University Hospital Whipps Cross Road Leytonstone London, UK

Email: Gurpreet Singh-Ranger\* - [gsinghranger@yahoo.co.uk](mailto:gsinghranger@yahoo.co.uk); Andrew Sharp - [drandysharp@honkingweasel.freeserve.co.uk](mailto:drandysharp@honkingweasel.freeserve.co.uk);

James N Crinnion - [james.crinnton@whippsx.nhs.uk](mailto:james.crinnton@whippsx.nhs.uk)

\* Corresponding author

Published: 11 May 2004

Received: 28 January 2004

*International Seminars in Surgical Oncology* 2004, **1**:4

Accepted: 11 May 2004

This article is available from: <http://www.issoonline.com/content/1/1/4>

© 2004 Singh-Ranger et al; licensee BioMed Central Ltd. This is an Open Access article: verbatim copying and redistribution of this article are permitted in all media for any purpose, provided this notice is preserved along with the article's original URL.

### Abstract

Granulosa cell tumours of the ovary are rare, comprising around 3% of ovarian tumours. These tumours have preponderance for local spread and extremely late recurrence. Although previous cases of recurrence have been described, it is extremely unusual for these tumours to recur after thirty years. We describe a case of recurrence of granulosa cell tumour after 30 years, presenting as small bowel obstruction. The patient had not been followed up after the original surgery, and on histological analysis, recurrence of the original tumour was confirmed. This case report emphasises the necessity for lifelong follow-up of patients who have had these tumours excised, and also the unusual way in which these tumours can recur.

### Introduction

Granulosa cell tumours are uncommon sex cord-stromal tumours of the ovary, and comprise approximately 3% of all ovarian malignancies [1]. These tumours characteristically have a low malignant potential, and a tendency for local spread and high recurrence rates, sometimes many years after the original diagnosis [2,3].

We describe a case of granulosa cell tumour of the ovary, which recurred many years after the original surgery. Whilst there have been reports of recurrence of this tumour, recurrence after 30 years is extremely rare [4,5]. Moreover, to our knowledge, this is the first described case manifesting as small bowel obstruction.

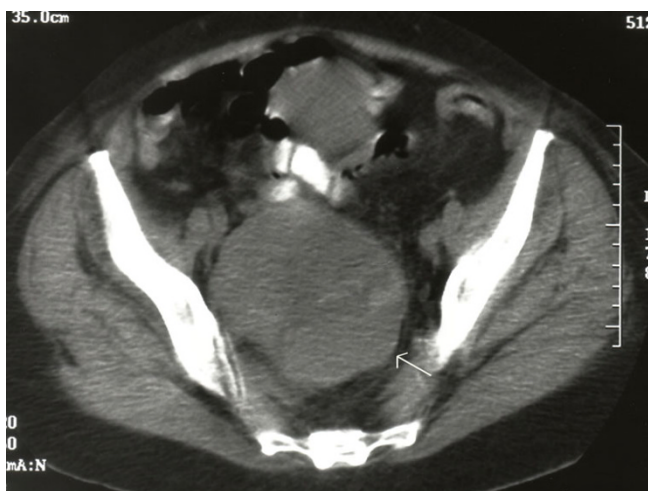
### Case Report

A 72 year old female was admitted from the emergency department with a five day history of abdominal pain, and markedly abnormal blood tests; haemoglobin 8.1 g/dl, white count  $11.2 \times 10^6$  /dl, urea 28.3 mmol/l, creati-

nine 409  $\mu\text{mol/l}$ . Physical examination revealed a large abdomen, non-distended, with diffuse tenderness, no guarding and normal bowel sounds.

Her past medical history was significant in that she was under haematological review for chronic normocytic, normochromic anaemia. This had been present for at least 20 months, and had been investigated with upper and lower gastrointestinal tract endoscopy, blood tests and ultrasound scanning all of which had been unremarkable.

There had also been one previous admission for acute abdominal pain 30 years earlier, and she had undergone laparotomy on the night of admission. Surgery revealed an enlarged right ovary with multiple solid areas, with rupture into the broad ligament. A total hysterectomy and bilateral salpingo-oophorectomy were performed. Histology revealed a mainly solid, large granulosa cell tumour of the ovary, with acute rupture. She was discharged uneventfully, and had not been followed up.



**Figure 1**

In the current admission, she was admitted for further investigation, and underwent a abdomino-pelvic contrast CT scan the next day. This revealed a large pelvic mass causing compression of the right ureter, and a right hydronephrosis (Figure 1, arrow).

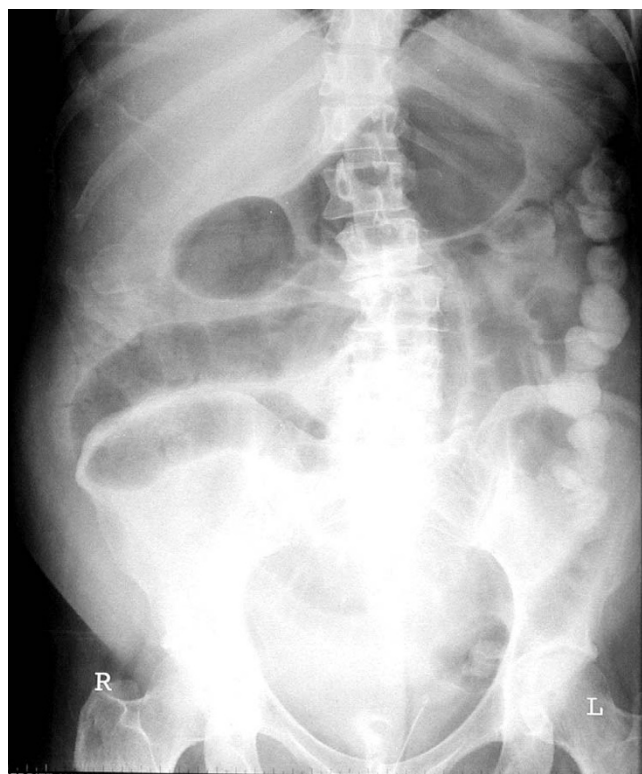
The next day, she developed nausea, vomiting and colicky abdominal pain, and a plain abdominal radiograph was ordered. This revealed dilated small bowel loops, and a diagnosis of small bowel obstruction was made (Figure 2). She did not respond to conservative management, and developed signs of small bowel strangulation after 24 hours.

At laparotomy, the terminal ileum was gangrenous in several places, and found to be tethered to a focal organised haematoma arising from a large retroperitoneal cystic mass behind the bladder. There was no blood elsewhere in the abdominal cavity.

The retroperitoneal mass was incised, with the resulting release of a haematoma of around 1 litre in quantity. This was evacuated from the cyst, together with a necrotic lesion in its centre, and sent for histology. A small bowel resection was performed, drains inserted and the abdomen closed.

She made an uneventful recovery, with full resolution of her renal function, and anaemia.

Subsequent histology revealed a sex cord – stromal tumour of ovary, characterised as a poorly differentiated granulosa cell tumour. The small bowel was also involved



**Figure 2**

by tumour. An immunohistochemical review of her original tumour from thirty years prior was performed, and confirmed that a recurrence of the original lesion had occurred.

She was referred to a specialist oncological centre for further management and presently remains asymptomatic and disease-free.

### Discussion

The tendency for late recurrence makes granulosa cell tumours unique amongst malignant ovarian tumours. It is thought that recurrent tumours arise from peritoneal seeds which begin at a point of contact between the primary tumour and a lower abdominal or pelvic structure [6]. These lesions then remain after surgical excision of the primary tumour, and grow extremely slowly as discrete masses, displacing adjacent structures and organs, but only infrequently invading them. Overall time to recurrence from initial surgery varies greatly. On review of the literature, our case is the second reported case of recurrence after 30 years [5].

There is a recognised association between granulosa cell tumour and haemoperitoneum [7,8]. Previous reports have described cases presenting as an acute abdomen [9,10]. Our case is unique in that it is likely our patient underwent chronic blood loss into the pelvic mass, resulting in anaemia, with a subsequent acute episode of bleeding prior to admission resulting in a large increase in the size of the pelvic mass, and a limited haemoperitoneum. The presence of the pelvic mass caused ureteric obstruction and hydronephrosis, whilst adherence of the terminal ileum to the adjacent organising intra-abdominal haematoma resulted in small bowel obstruction.

At her original surgery, our patient was found to have a large tumour, with acute rupture. Histology did not reveal any untoward prognostic features.

Predictors for recurrence may include advanced stage at presentation, high tumour mitotic count, bilaterality, large tumour size, tumour rupture, and lymphatic space invasion [11-13], although other studies have refuted the correlation of these criteria with risk of relapse [14]. More recently, molecular markers such as Ki-67 and p53 overexpression have been linked to a higher recurrence risk and poor survival [15]. The polypeptide hormone inhibin may be useful as a marker for the diagnosis of recurrent tumours. Inhibin is produced by granulosa cells, and should be absent in the oophorectomised, post-menopausal female [16]. In one prospective study, serum inhibin levels became elevated up to 2 years before surgery was performed for recurrent disease [17].

Recurrent tumours can be treated with surgical resection, post-operative chemotherapy or radiotherapy. Surgery is considered palliative, and repeated surgical debulking has been described as a successful method of controlling symptoms and prolonging survival [1]. Although combination chemotherapy regimens with cisplatin, vinblastine and bleomycin (PVB) have demonstrated response rates of over 90%, impact on disease-free and long term survival is currently unknown.

The relatively small numbers of patients available for study together with the fact that recurrences may occur extremely late has meant that randomised controlled trials to assess the relative effectiveness of surgery over chemo- or radiotherapy are not feasible.

In conclusion, this report reiterates that recurrence of granulosa cell tumours can occur many years after the original diagnosis. Moreover, recurrent tumours can present with unexpected symptoms. It is imperative that patients who have been given this diagnosis have lifelong follow-up.

## Acknowledgements

Written consent was obtained from the patient for publication of this case report.

## References

1. Segal R, DePetrillo AD, Thomas G: **Clinical review of adult granulosa cell tumours of the ovary.** *Gynecol Oncol* 1995, **56**:338-344.
2. Haba R, Miki H, Kobayashi S, Ohmori M: **Combined analysis of flow cytometry and morphometry of ovarian granulosa cell tumour.** *Cancer* 1993, **72**:3258-3262.
3. Gerhenson DM: **Chemotherapy of ovarian germ cell and sex cord stromal tumours.** *Semin Surg Oncol* 1994, **10**:290-298.
4. Li MKW, van der Walt JD: **Recurrent granulosa cell tumour of the ovary 22 years after primary excision.** *J R Coll Surg Edinb* 1984, **29**(3):192-194.
5. Hines JF, Khalifa MA, Moore JL, Fine KP, Lage JM, Barnes WA: **Recurrent granulosa cell tumour of the ovary 37 years after initial diagnosis: a case report and review of the literature.** *Gynecol Oncol* 1996, **60**:484-488.
6. Lusch CJ, Mercurio TM, Runyeon WK: **Delayed recurrence and chemotherapy of a granulosa cell tumor.** *Obstet Gynecol* 1978, **51**(4):505-507.
7. FRENCH WG: **The clinical behaviour of the granulosa-cell tumour of the ovary.** *Am J Obstet Gynecol* 1951, **62**:75-83.
8. Lee WL, Yuan CC, Lai CR, Wang PH: **Haemoperitoneum is an initial presentation of recurrent granulosa cell tumours of the ovary.** *Jpn J Clin Oncol* 1999, **29**(10):509-512.
9. Gondos B, Monroe SA: **Cystic granulosa cell tumour with massive haemoperitoneum.** *Obstet Gynecol* 1971, **38**(5):683-689.
10. Poma PA: **Haemoperitoneum in a postmenopausal woman.** *J Natl Med Assoc* 1998, **90**(5):317-319.
11. Miller BE, Barron BA, Wan JW, Delmore JE, Silva EG, Gershenson DM: **Prognostic factors in adult granulosa cell tumour of the ovary.** *Cancer* 1997, **79**:1951-1955.
12. Savage P, Constenla D, Fisher C, Shepherd JH, Barton DP, Blake P, et al.: **Granulosa cell tumours of the ovary: demographics, survival and the management of advanced disease.** *Clin Oncol (R Coll Radiol)* 1998, **10**:242-245.
13. Malstrom H, Hogberg T, Risberg B, Simonsen E: **Granulosa cell tumours of the ovary: prognostic factors and outcome.** *Gynecol Oncol* 1994, **52**:50-55.
14. Lauszus FF, Petersen AC, Greisen J, Jakobsen A: **Granulosa cell tumour of the ovary: a population-based study of 37 women with stage I disease.** *Gynecol Oncol* 2001, **81**:456-460.
15. Wabersich J, Fracas M, Mazzer S, Marchettie M, Altavilla G: **The value of prognostic factors in ovarian granulosa cell tumours.** *Eur J Gynaecol Oncol* 1998, **19**:69-72.
16. Lappohn RE, Burger HG, Bouma J, Bangah M, Krans M: **Inhibin as a marker for granulosa cell tumour.** *Acta Obstet Gynecol Scand Suppl* 1992, **155**:61-65.
17. Jobling T, Marners P, Healy DL, MacLachlan V, Burger HG, Quinn M, Rome R, Day AJ: **A prospective study of inhibin in granulosa cell tumours of the ovary.** *Gynecol Oncol* 1994, **55**:285-289.

Publish with **BioMed Central** and every scientist can read your work free of charge

"BioMed Central will be the most significant development for disseminating the results of biomedical research in our lifetime."

Sir Paul Nurse, Cancer Research UK

Your research papers will be:

- available free of charge to the entire biomedical community
- peer reviewed and published immediately upon acceptance
- cited in PubMed and archived on PubMed Central
- yours — you keep the copyright

Submit your manuscript here:  
[http://www.biomedcentral.com/info/publishing\\_adv.asp](http://www.biomedcentral.com/info/publishing_adv.asp)

