

Case report

Open Access

Reconstruction after external hemipelvectomy using tibia-hindfoot rotationplasty with calcaneo-sacral fixation

George YX Kong¹, Hannes A Rudiger¹, Eugene TH Ek¹, Wayne A Morrison² and Peter FM Choong*¹

Address: ¹Department of Orthopaedic Surgery, St. Vincent's Hospital, Melbourne, Australia and ²Department of Plastic Surgery, St. Vincent's Hospital, Melbourne, Australia

Email: George YX Kong - gkong008@hotmail.com; Hannes A Rudiger - hannes.ruediger@mm.st; Eugene TH Ek - eugene_ek@msn.com; Wayne A Morrison - wajm@unimelb.edu.au; Peter FM Choong* - sarcoma@bigpond.net.au

* Corresponding author

Published: 21 January 2008

Received: 25 October 2007

International Seminars in Surgical Oncology 2008, **5**:1 doi:10.1186/1477-7800-5-1

Accepted: 21 January 2008

This article is available from: <http://www.issoonline.com/content/5/1/1>

© 2008 Kong et al; licensee BioMed Central Ltd.

This is an Open Access article distributed under the terms of the Creative Commons Attribution License (<http://creativecommons.org/licenses/by/2.0>), which permits unrestricted use, distribution, and reproduction in any medium, provided the original work is properly cited.

Abstract

Background: External hemipelvectomy is associated with high post operative morbidity and a poor functional outcome. We aim to explore a reconstruction technique to improve function and post operative appearance for patients who undergo external hemipelvectomy.

Case presentation: We present a Case where extensive cancer involvement of pelvis and femur was managed with a novel surgical technique, which involved a calf sparing modified anterior flap hemipelvectomy combined with rotationplasty of the spared calf and fixation of calcaneus to the sacrum, thereby recreating a new thigh stump.

Conclusion: Tibia-hindfoot rotationplasty result in good functional outcome and appearance for selected patients undergoing external hemipelvectomy with unaffected external iliac and femoral vessels.

Background

Despite the advent of increasingly effective chemotherapy and limb-salvage surgery, external hemipelvectomy may remain the only surgical treatment for extensive tumors arising from the hip or pelvis. It is also a potential life-saving procedure for patients with massive pelvic trauma and uncontrollable sepsis of the lower limb. Unfortunately, external hemipelvectomy is often associated with high morbidity and poor quality of life for patients. Postoperative appearance following conventional external hemipelvectomy is also often poor, resulting in body image issues.

We here present a novel reconstructive technique aiming to improve function and appearance for patients requiring

external hemipelvectomy. This technique is applicable in selected patient with unaffected external iliac and femoral vessels (i.e. most patients who would otherwise qualify for an anterior flap hemipelvectomy). The reconstruction involves a modified anterior flap hemipelvectomy with resection of the femur and hemipelvis but preservation of below knee structures. The calf with its vascular supply is rotated by 180 degrees. The fore- and mid-foot are then resected. The calcaneus is then fixed to the osteotomy site at the sacrum, thereby recreating a new thigh stump.

Case presentation

68 year-old female presented to our unit with a 10 year history of recurrent malignant fibrohistiocytoma involv-

ing left pelvis and femur. She was initial treated 10 years ago with radical radiotherapy, following which she developed local recurrence after 5 years. Due to the extensive involvement of hemipelvis and proximal femur, a type II hemipelvectomy and reconstruction with saddle prosthesis was performed. The surgery was complicated by methicillin-resistant staphylococcus aureus (MRSA) infection for which she was managed with surgical washout and long term suppressive antibiotic treatment. She represented to our unit 5 years following saddle-prosthesis surgery with local tumor recurrence within the pelvis and surrounding the prosthesis. (Figure 1) No systemic recurrence was detected on chest CT, whole body Tc⁹⁹-bone scan or Thallium scan. Following a course of neoadjuvant radiation therapy, surgical resection and reconstruction was performed as detailed below.

Operative Technique

The resection technique was a variant of the anterior flap hemipelvectomy described by Sugarbaker and Chretien [1]. The patient was positioned in a floppy semi-lateral position on the operation table. Skin incision was made as shown. (Figure 2) In brief, skin incision commenced proximal to the anterior superior iliac spine aiming posterior and parallel to the iliac crest. The incision then curved around the posterior superior iliac spine and ran inferiorly approximately 5 cm lateral to the anus. It then ran along the medial aspect of the thigh towards the medial femoral condyle, traversed the popliteal fossa to the lateral con-

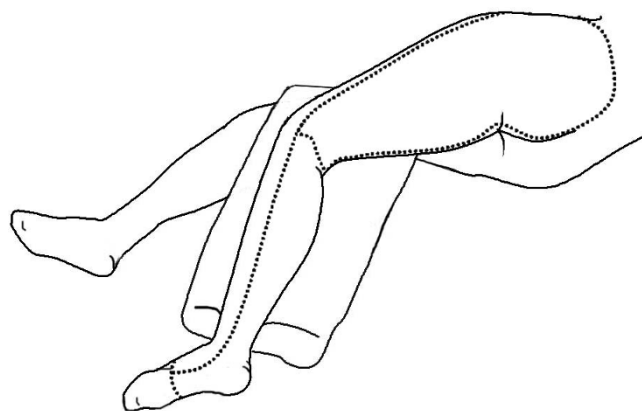


Figure 2
Diagrammatic outline of skin incision (posterior lateral view).

dyle and returned to the anterior superior iliac spine along the lateral aspect of the thigh.

Dissection at the level of pelvis and proximal thigh was performed with the aim to preserve the calf. Briefly, deep dissection commenced proximal to the iliac crest, where the abdominal wall musculature was divided. The internal aspect of the iliac muscle and the sacroiliac joint were dissected, thereby dividing the sacral plexus.

A musculocutaneous anterior thigh flap comprising quadriceps and parts of the adductor compartment was then elevated based superficially. Along the medial thigh incision, the superficial femoral artery and vein were identified at the level of the adductor canal underneath the sartorius muscle and the vessels were skeletonized distally into the popliteal fossa keeping the blood supply to both heads of the gastrocnemius intact to for the basis of a filleted musculoskeletal calf flap. The tibial nerve and the common peroneal nerve were divided at this level. The knee joint was then disarticulated and the patella resected. The musculocutaneous thigh flap is further developed by elevating the quadriceps muscles and adductor muscles from the femur. The muscular flap, which is in continuity with the calf (superficial femoral and popliteal vessels and saphenous nerve intact), is then retracted anteriorly to allow adequate access to the hip and pelvis. The adductors are detached from the pubis and the symphysis is divided.

From posterior, the medial origin of the gluteus maximus was elevated from the sacrum. An osteotomy was performed through sacrum from the greater sciatic notch laterally to approximately 1 cm medial to the sacroiliac joint. Ileo-lumbar, sacro-tuberal and sacro-spinal ligaments are divided. Under external rotation of the hemipelvis, the hemipelvis, tumour mass and femur were delivered *en-bloc*.

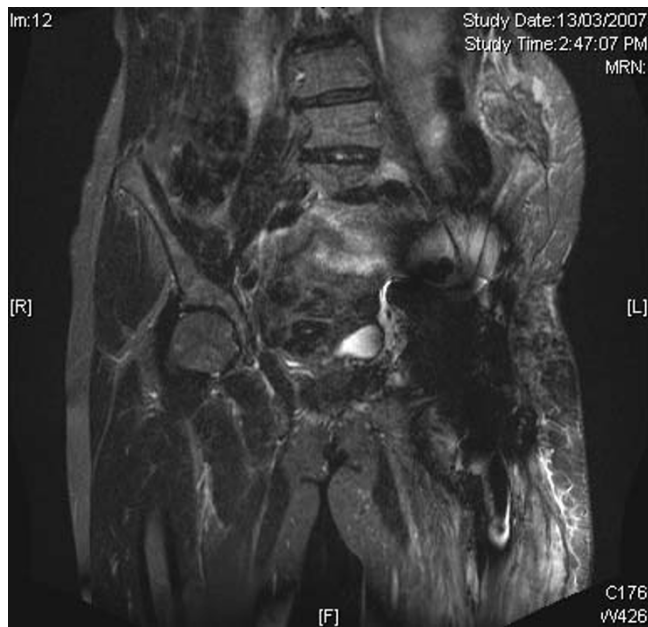

Figure 1
Pre-Operative MRI coronal view of Case Patient showing local cancer recurrence involving left pelvis and surrounding the saddle prosthesis.

Preparation of rotational flap

The rotational tibia-hindfoot flap was supplied by the superficial femoral artery and vein. A skin incision was made from the lateral end of the popliteal crease parallel to the fibula down to the posterior aspect of the lateral malleolus. A fillet flap consisting of superficial posterior muscle compartment and overlying skin was developed from the lateral calf incision (vascularized by perforators through the soleus and gastrocnemius muscles). A fillet flap of the foot was made based on the dorsalis pedis pedicle dorsally and the posterior tibial pedicle medially. The ankle and subtalar joints were preserved. The osseous forefoot was amputated through the transverse tarsal joint (Chopart).

The tibia-hindfoot flap was then rotated such that the lateral aspect of the calcaneus came in contact with the ileosacral osteotomy. The calcaneus was the fixed to the sacrum with two sternal wire cerclages. (Figure 3) The quadriceps muscle flap was then sutured to the fillet flap on the calf, thereby forming a neo-thigh stump. Surgery was completed with skin closure.

Post Operative Course

Postoperatively, the patient remained non-weight bear on the neo-thigh. The stump was held in a flexed position (70 degrees) in a brace to allow for a pseudo-arthrosis to develop between the calcaneus and the ileosacral osteot-

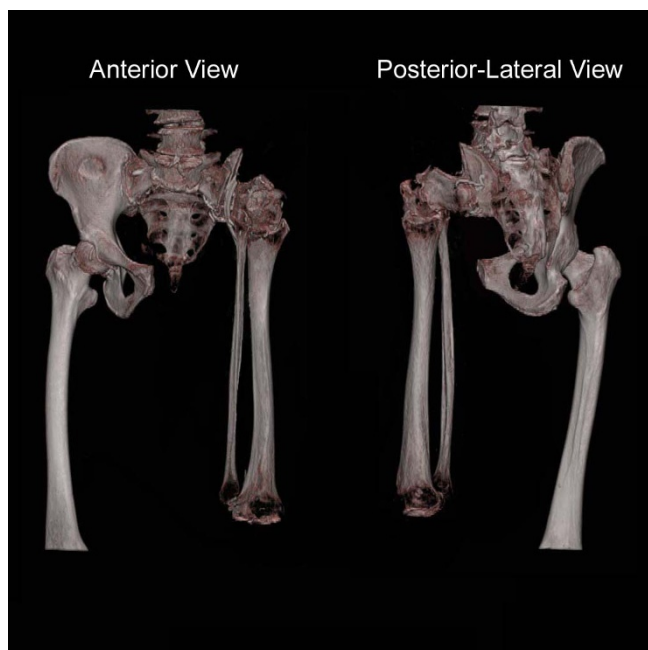


Figure 3
Post operative 3D reconstruction of pelvis and neo-thigh. Note the 180 degree rotation of tibia-fibula and fixation of calcaneus to ileosacral osteotomy site.

omy. Two weeks following the operation, the patient developed superficial wound breakdown at the posterior aspect of her buttock. After surgical debridement and wound closure, no further complications occurred. No phantom limb pain developed. By two months post op, patient was able to sit upright comfortably and ambulate with two crutches. (Figure 4)

Discussion

Wide resection remains an important principle in the treatment of bone and soft tissue sarcomas. Despite the fact that the majority of patients with pelvic sarcomas can be safely treated with chemotherapy and limb-salvage surgery, [2] in a number of patients external hemipelvectomy is still required to achieve wide margins. Techniques used for soft tissue coverage following external hemipelvectomy include the posterior flap and the anterior flap closure [3,4]. These techniques aim to achieve tissue coverage but is often associated with high morbidity and poor functional outcomes [5,6]. Post operatively the majority of patients are either unable to ambulate without the use of crutches (80%) or remaining wheelchair bound or bed bound (15%); only around 5% of patients are eventually able to ambulate with prosthesis [7]. Well-fitted prosthesis for post-external hemipelvectomy patients is difficult to produce and the energy requirement to ambulate with prosthesis is very high. For patients who had external hemipelvectomy even the ability to sit upright can be difficult without a well-fitted sitting socket because of the lack of an ischium. Psychological issues surrounding body image following external hemipelvectomy is also significant and requires extensive pre and pos operative counseling [8].

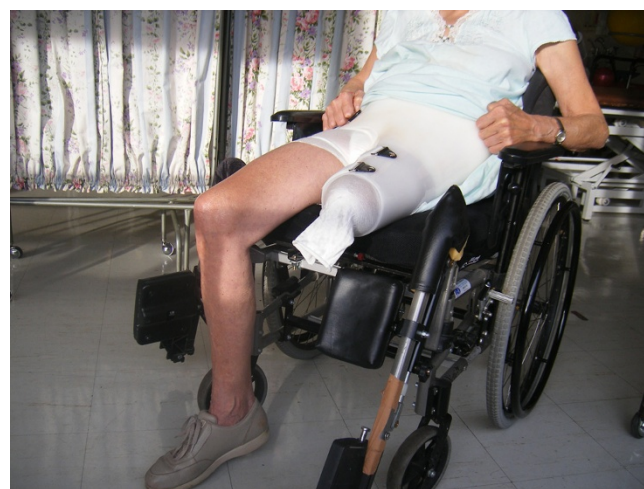

Figure 4
Clinical appearance of Case Patient 2 months following operation. Case Patient was able to sit upright comfortably with brace and was able to ambulate independently with crutches.

Reconstructive surgery in our Case involved the combination of external hemipelvectomy with a rotation tibia-hindfoot flap resulting in the fixation of calcaneus to the ileosacral osteotomy. The calcaneus tubercle functions as a neo-ischium and the tibia-hindfoot flap functions as a neo-thigh. This allows the patient to sit upright without the aid of a sitting socket. Cosmetically, the surgery results in an apparent above knee stump.

Peterson *et al* had previously described two cases of tibia-hindfoot rotationplasty with calcaneopelvic arthrodesis for infective complications involving the proximal femur. In both cases no parts of the bony pelvis had been resected and the calcaneus could be fixed to the acetabulum. Movement was allowed as a result of retained tibiotalar and subtalar joints. Post operatively these patients were able to tolerate full weight bear with the use of a standard above knee amputation prosthesis [9]. Similar tibial turn-up procedure to manage distal femoral bone loss has also been described in pediatric patients with good functional result [10,11]. The surgical resection in our Case was much more extensive, with the removal of entire hemipelvis and femur. Despite this the patient in our Case has made excellent recovery with good sitting function and cosmetically satisfactory result.

Conclusion

The Case illustrates that the use of the novel technique of tibia-hindfoot rotationplasty can result in good functional outcome and appearance for selected patients undergoing external hemipelvectomy with unaffected external iliac and femoral vessels.

Competing interests

The author(s) declare that they have no competing interests.

Acknowledgements

Written informed consent was obtained from the patient for publication of this Case report and any accompanying images. A copy of the written consent is available for review by the Editor-in-Chief of this journal.

References

1. Sugarbaker PH, Chretien PA: **Hemipelvectomy for buttock tumors utilizing an anterior myocutaneous flap of quadriceps femoris muscle.** *Ann Surg* 1983, **197**:106-115.
2. Choong PF: **Review article: Reconstructive surgery following resection of primary and secondary tumours of the hip.** *J Orthop Surg (Hong Kong)* 2000, **8**:83-94.
3. Chretien PA, Sugarbaker PH: **Surgical technique of hemipelvectomy in the lateral position.** *Surgery* 1981, **90**:900-909.
4. Karakousis CP, Vezzeridis MP: **Variants of hemipelvectomy.** *Am J Surg* 1983, **145**:273-277.
5. Wirbel RJ, Schulte M, Mutschler WE: **Surgical treatment of pelvic sarcomas: oncologic and functional outcome.** *Clin Orthop Relat Res* 2001:190-205.
6. Ham SJ, Schraffordt Kooops H, Veth RP, van Horn JR, Eisma WH, Hoekstra HJ: **External and internal hemipelvectomy for sarcomas of the pelvic girdle: consequences of limb-salvage treatment.** *Eur J Surg Oncol* 1997, **23**:540-546.
7. Appfelstaedt JP, Driscoll DL, Spellman JE, Velez AF, Gibbs JF, Karakousis CP: **Complications and outcome of external hemipelvectomy in the management of pelvic tumors.** *Ann Surg Oncol* 1996, **3**:304-309.
8. Sneppen O, Johansen T, Heerfordt J, Dissing I, Petersen O: **Hemipelvectomy. Postoperative rehabilitation assessed on the basis of 41 cases.** *Acta Orthop Scand* 1978, **49**:175-179.
9. Peterson CA 2nd, Koch LD, Wood MB: **Tibia-hindfoot osteomusculocutaneous rotationplasty with calcaneopelvic arthrodesis for extensive loss of bone from the proximal part of the femur. A report of two cases.** *J Bone Joint Surg Am* 1997, **79**:1504-1509.
10. Winkelmann WW: **Type-B-IIIa hip rotationplasty: an alternative operation for the treatment of malignant tumors of the femur in early childhood.** *J Bone Joint Surg Am* 2000, **82**:814-828.
11. McDonald DJ, Scott SM, Eckardt JJ: **Tibial turn-up for long distal femoral bone loss.** *Clin Orthop Relat Res* 2001:214-220.

Publish with **BioMed Central** and every scientist can read your work free of charge

"BioMed Central will be the most significant development for disseminating the results of biomedical research in our lifetime."

Sir Paul Nurse, Cancer Research UK

Your research papers will be:

- available free of charge to the entire biomedical community
- peer reviewed and published immediately upon acceptance
- cited in PubMed and archived on PubMed Central
- yours — you keep the copyright

Submit your manuscript here:
http://www.biomedcentral.com/info/publishing_adv.asp

