

Case report

Open Access

Hemorrhage associated with hepatic artery pseudoaneurysms after regional chemotherapy with floxuridine: case report

Panagiotis Samaras*¹, Thomas Pfammatter² and Bernhard C Pestalozzi¹

Address: ¹Department of Oncology, University Hospital Zurich, Zurich, Switzerland and ²Institute of Diagnostic Radiology, University Hospital Zurich, Zurich, Switzerland

Email: Panagiotis Samaras* - panagiotis.samaras@usz.ch; Thomas Pfammatter - thomas.pfammatter@usz.ch; Bernhard C Pestalozzi - bernhard.pestalozzi@usz.ch

* Corresponding author

Published: 11 July 2008

Received: 9 May 2008

International Seminars in Surgical Oncology 2008, **5**:17 doi:10.1186/1477-7800-5-17

Accepted: 11 July 2008

This article is available from: <http://www.issoonline.com/content/5/1/17>

© 2008 Samaras et al; licensee BioMed Central Ltd.

This is an Open Access article distributed under the terms of the Creative Commons Attribution License (<http://creativecommons.org/licenses/by/2.0>), which permits unrestricted use, distribution, and reproduction in any medium, provided the original work is properly cited.

Abstract

Pseudoaneurysms of the hepatic artery are a rare complication in patients with primary or secondary liver tumors treated with intra-arterial chemotherapy. We present two patients who developed this complication after placement of a catheter system into the gastroduodenal artery and initiation of regional chemotherapy with floxuridine. Diagnosis was made after symptomatic bleeding occurred, necessitating emergency angiography with coil embolization. Pseudoaneurysms usually occur after mechanical damage of the vessel wall, but the chemical toxicity of floxuridine may add to the development of vascular impairment.

Background

Hepatic artery chemotherapy (HAC) was developed in the early 1960s to treat large, unresectable primary and secondary liver tumors [1,2]. This approach is based on the rationale that local therapy through the hepatic artery increases the exposure of the liver tumors to cytotoxic agents, leading to higher response rates while limiting systemic side effects like myelosuppression, mucositis and diarrhea. Surgical or percutaneous placement of a subcutaneous device allows chemotherapy to be delivered continuously into the gastroduodenal artery via a catheter. Regional chemotherapy predominantly for the treatment of colorectal liver metastases was increasingly used in the late 1980s and 1990s because of the limited efficacy of available systemic treatment options [3-9]. This approach was also evaluated in the treatment of unresectable primary liver tumors and as adjuvant treatment after metastasectomy [10-14]. However, the application of floxuridine-deoxy-ribose (FUDR), a prodrug of 5-fluorouracil (5-FU) with a high liver extraction fraction, into the

hepatic artery can cause several complications. Biliary toxicity is the dose limiting side effect of HAC with FUDR, usually indicated by an increase of bilirubin and liver enzymes [15-18]. Other infrequent complications are gastric and duodenal ulcerations, mainly due to misperfusion. Rarely thrombosis, nausea, vomiting and diarrhea occur [16,19,20]. Pocket infections, development of cholangitis and liver abscesses have also been reported [21].

A rare complication of HAC is the formation of pseudoaneurysms of the hepatic artery. In this article we describe two patients who developed aneurysmatic cavities of the hepatic artery after regional chemotherapy with FUDR and presented with hemorrhage.

Case presentation

Case 1

A 62-year-old male patient presented in May 2001 with initially unresectable metachronous liver metastases of a

surgically treated rectal carcinoma. Cholecystectomy and implantation of an infusion system (Arrow pump, Codman 3000, Johnson & Johnson, Raynham, Mass.) were carried out by laparotomy. From June 2001 to October 2001 he received four cycles of neoadjuvant HAC with FUDR monotherapy in a total dose of 1100 mg. In November 2001 hemihepatectomy of the right lobe could be performed after downsizing of the metastases. Five months later, he developed a solitary liver metastasis. In April 2002 a wedge-resection was performed, followed by one cycle of adjuvant HAC with FUDR in May 2002. 15 days after restart of regional therapy the patient presented with abdominal pain. Computed tomography revealed a large retroperitoneal hematoma and a ruptured pseudoaneurysm of the hepatic artery at the site of the catheter tip.

In a subsequent angiography via a transfemoral access a stent-graft was placed into the hepatic artery in order to preserve arterial hepatic perfusion. This led only to a partial exclusion of the aneurysm and was complicated by a dissection of the hepatic artery, reflecting its friability. Definitive treatment was finally achieved by coil embolization (Figures 1, 2). After clinical stabilization, the pump system was removed. Regional therapy was discontinued and the patient recovered uneventfully.

Case 2

A 38-year-old female patient was diagnosed with a multifocal hepatocellular carcinoma in July 2000. Hemihepatectomy of the right lobe, resection of segment I and cryosurgery of a satellite lesion in segment II were performed one month later. Because of recurrence of the tumor, a wedge resection of segment III/IV followed in

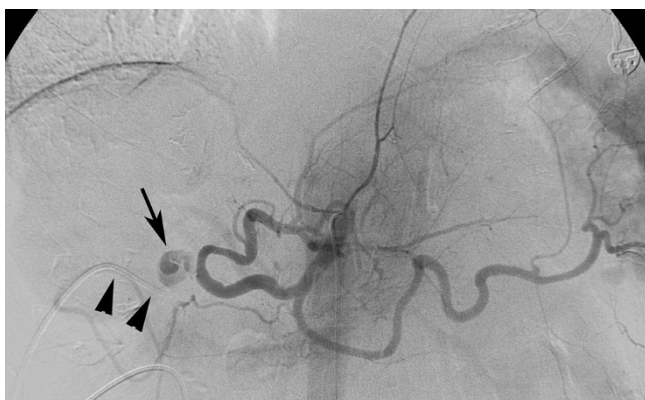


Figure 1
Celiac angiogram. The celiac angiogram shows a pseudoaneurysm (arrow) of the proper hepatic artery located next to the origin of the gastroduodenal artery, which is occluded by the chemotherapy infusion catheter (arrowheads). The right hepatic artery is missing after hemihepatectomy.

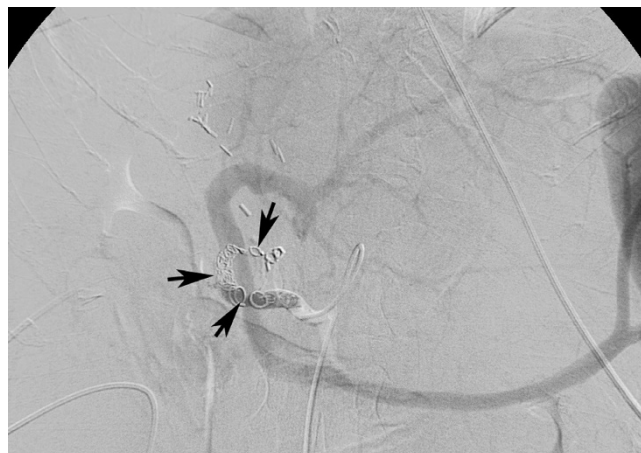

Figure 2
Completion celiac angiogram. In the completion celiac angiogram the common hepatic artery is occluded by the microcoils (arrows). The liver is supplied uniquely by the patent portal vein.

February 2001. Concurrently, an Arrow pump system was implanted in a subcutaneous pocket on the lower right side of the abdomen. The catheter tip was placed at the origin of the gastroduodenal artery. From May 2001 to September 2001 she received HAC with 5 cycles of FUDR in a total dose of 600 mg to slow down tumor growth until orthotopic liver transplantation could be performed. In October 2001 the treatment had to be discontinued because of biliary toxicity with elevated liver enzymes and bilirubin. Five months later she had progressive disease and HAC was started again. Because of the previous toxicity, FUDR was administered in reduced dose. After completion of the fourth cycle, she presented to our emergency room with jaundice, fever and epigastric pain in June 2002. She was hospitalized and antibiotic treatment with ciprofloxacin was started. After isolation of *Klebsiella pneumoniae* from the blood culture, antibiotic treatment was changed to piperacillin and tazobactam. Percutaneous transhepatic cholangiography showed multiple liver abscesses. A few days later the patient developed severe hematemesis and melena necessitating blood transfusions. Gastroscopy showed blood remnants without any lesions of the gastrointestinal mucosa and hemobilia was seen in a repeated cholangiogram. Finally, computed tomography revealed a pseudoaneurysm of a segmental left hepatic artery, about 5 cm from the site of the catheter tip close to the hepato-enteric anastomosis (Figure 3). The development of a hepatic artery-biliary fistula was assumed to be the cause of the gastrointestinal bleeding.

Angiography was performed via a transfemoral access, and after placement of a 4 French catheter in the segmen-

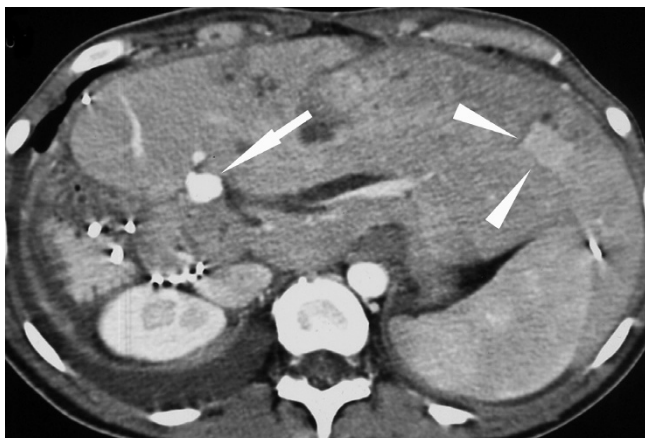


Figure 3
Contrast-enhanced abdominal CT. The left liver lobe is hypertrophied after extended right hemihepatectomy. There is an arterial pseudoaneurysm (*arrow*) close to the hepatoenteric anastomosis. A hypervascular metastasis is depicted on the same cut (*arrowheads*).

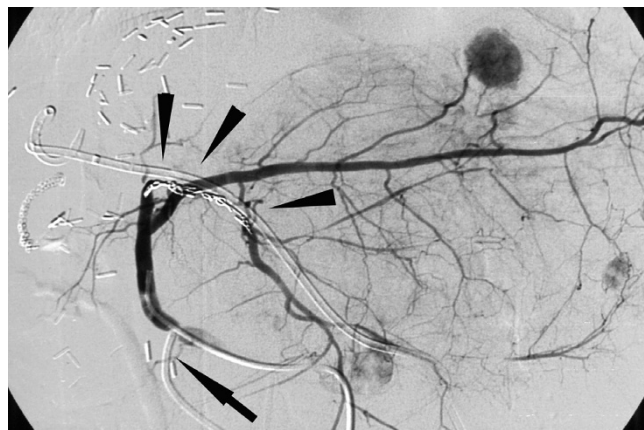

Figure 5
Completion hepatic arteriogram. Coils in the segmental artery III (*arrowheads*) after embolisation. Due to hepatic redistribution the embolized segmental artery is opacified distally to the coils. A hepatic chemotherapy infusion catheter had been inserted into the gastroduodenal artery (*arrow*).

tal artery the aneurysm was occluded by coil embolization (Figures 4, 5). A few days later, the fever and jaundice resolved completely. The arrow pump was removed and no further chemotherapy was applied. The patient recovered uneventfully.

Discussion

Pseudoaneurysms of the hepatic artery due to placement of a catheter into the gastroduodenal artery and treatment with continuous regional chemotherapy are described infrequently in the literature [9,13,22]. They can remain clinically silent even after continuation of the treatment [23]. A few case reports describe the development of hemorrhage after rupture of the pseudoaneurysm or fistulation to a bile duct or the intestine [24-26].

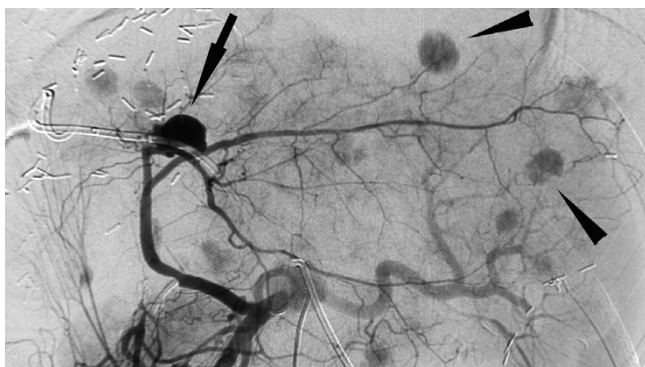


Figure 4
Celiac angiogram. Celiac angiogram with pseudoaneurysm of a left segmental artery (*arrow*) and disseminated metastases (*arrowheads*).

Pseudoaneurysms usually develop after percutaneous or surgical procedures as a result of dissection of the vessel. A penetrating trauma leads to a disruption of the media without blood seepage through the adventitia. The late development after multiple courses of intra-arterial chemotherapy, as described in our two patients, emphasises the role of HAC as a potential cause. Hepatic artery aneurysms account for 20% of all visceral aneurysms [27]. The rate of rupture was reported to be as high as 65%, with a mortality rate of 20% [28]. Symptoms of rupture include abdominal pain in case of retroperitoneal bleeding and hematemesis or melena, if the aneurysm is in contact with the biliary tract or the duodenal lumen. Early interventional therapy is necessary to control hemorrhage. The preferred approach is a hepatic angiography with subsequent coil embolization because pseudoaneurysms are usually located adjacent to the hilum of the liver, making surgery difficult [29-33]. Major risks of this procedure include arterial dissection, artery occlusion, thromboembolic phenomena and intraprocedural rupture of the aneurysm. Recently, promising results were reported with endovascular stent-graft placement, but long-term results are still lacking [34,35]. There are also reports of successful treatment with computed tomography guided percutaneous embolization and ultrasound guided percutaneous thrombin injection [36,37].

Considering the development and widespread use of more effective systemic chemotherapy, the use of regional chemotherapy decreased in the last years. A recent meta-analysis showed that FUDR-based HAC alone does not improve response rates and outcome compared with 5-FU based combination chemotherapy [38]. However, the role

of regional chemotherapy with FUDR in primary liver tumors and in combination with efficient systemic chemotherapy in colorectal liver metastases has not been defined yet. HAC should be utilized only in high-volume centers with expertise in this field due to the high technical demands of this procedure, since the rate of complications is clearly related to the surgeon's experience [39]. Clinicians should be aware of the possibly life threatening complications in patients treated with HAC. Because of the unpredictable course of pseudoaneurysms, early treatment with interventional radiological techniques should be considered. In the case of our two patients, angiography with coil embolization was necessary to control the critical condition.

Conclusion

Hepatic artery pseudoaneurysms may complicate regional chemotherapy with floxuridine. Prompt angiography with coil embolization is the preferred treatment to avoid life threatening hemorrhage in these patients.

Consent

Both patients gave written informed consent for publication of their data for scientific purposes.

Competing interests

The authors declare that they have no competing interests.

Authors' contributions

PS and BCP collected the data and wrote the article. TP provided the angiography pictures, contributed to the analysis and interpretation of the data and revised the manuscript. All authors read and approved the final manuscript.

References

- Clarkson B, Young C, Dierick W, Kuehn P, Kim M, Berrett A, Clapp P, Lawrence W Jr.: **Effects of continuous hepatic artery infusion of antimetabolites on primary and metastatic cancer of the liver.** *Cancer* 1962, **15**:472-488.
- Sullivan RD, Norcross JW, Watkins E Jr.: **Chemotherapy of Metastatic Liver Cancer by Prolonged Hepatic-Artery Infusion.** *The New England journal of medicine* 1964, **270**:321-327.
- Chang AE, Schneider PD, Sugarbaker PH, Simpson C, Culnane M, Steinberg SM: **A prospective randomized trial of regional versus systemic continuous 5-fluorodeoxyuridine chemotherapy in the treatment of colorectal liver metastases.** *Annals of surgery* 1987, **206**(6):685-693.
- Kemeny N, Daly J, Reichman B, Geller N, Botet J, Oderman P: **Intra-hepatic or systemic infusion of fluorodeoxyuridine in patients with liver metastases from colorectal carcinoma. A randomized trial.** *Annals of internal medicine* 1987, **107**(4):459-465.
- Kemeny NE, Niedzwiecki D, Hollis DR, Lenz HJ, Warren RS, Naughton MJ, Weeks JC, Sigurdson ER, Herndon JE 2nd, Zhang C, Mayer RJ: **Hepatic arterial infusion versus systemic therapy for hepatic metastases from colorectal cancer: a randomized trial of efficacy, quality of life, and molecular markers (CALGB 9481).** *J Clin Oncol* 2006, **24**(9):1395-1403.
- Rougier P, Laplanche A, Huguier M, Hay JM, Ollivier JM, Escat J, Salmon R, Julien M, Rouillet Audy JC, Gallot D, et al.: **Hepatic arterial infusion of floxuridine in patients with liver metastases from colorectal carcinoma: long-term results of a prospective randomized trial.** *J Clin Oncol* 1992, **10**(7):1112-1118.
- Wagman LD, Kemeny MM, Leong L, Terz JJ, Hill LR, Beatty JD, Kokal WA, Riihimaki DU: **A prospective, randomized evaluation of the treatment of colorectal cancer metastatic to the liver.** *J Clin Oncol* 1990, **8**(11):1885-1893.
- Hohn DC, Stagg RJ, Friedman MA, Hannigan JF Jr., Rayner A, Ignoffo RJ, Acord P, Lewis BJ: **A randomized trial of continuous intra-venous versus hepatic intraarterial floxuridine in patients with colorectal cancer metastatic to the liver: the Northern California Oncology Group trial.** *J Clin Oncol* 1989, **7**(11):1646-1654.
- Martin JK Jr., O'Connell MJ, Wieand HS, Fitzgibbons RJ Jr., Mailliard JA, Rubin J, Nagorney DM, Tschetter LK, Krook JE: **Intra-arterial floxuridine vs systemic fluorouracil for hepatic metastases from colorectal cancer. A randomized trial.** *Arch Surg* 1990, **125**(8):1022-1027.
- Clavien PA, Selzner N, Morse M, Selzner M, Paulson E: **Downstaging of hepatocellular carcinoma and liver metastases from colorectal cancer by selective intra-arterial chemotherapy.** *Surgery* 2002, **131**(4):433-442.
- Meric F, Patt YZ, Curley SA, Chase J, Roh MS, Vauthey JN, Ellis LM: **Surgery after downstaging of unresectable hepatic tumors with intra-arterial chemotherapy.** *Annals of surgical oncology* 2000, **7**(7):490-495.
- Tang ZY, Zhou XD, Ma ZC, Wu ZQ, Fan J, Qin LX, Yu Y: **Downstaging followed by resection plays a role in improving prognosis of unresectable hepatocellular carcinoma.** *Hepatobiliary Pancreat Dis Int* 2004, **3**(4):495-498.
- Kemeny N, Huang Y, Cohen AM, Shi W, Conti JA, Brennan MF, Bertino JR, Turnbull AD, Sullivan D, Stockman J, Blumgart LH, Fong Y: **Hepatic arterial infusion of chemotherapy after resection of hepatic metastases from colorectal cancer.** *The New England journal of medicine* 1999, **341**(27):2039-2048.
- Lorenz M, Muller HH, Schramm H, Gassel HJ, Rau HG, Ridwelski K, Hauss J, Stieger R, Jauch KW, Bechstein WO, Encke A: **Randomized trial of surgery versus surgery followed by adjuvant hepatic arterial infusion with 5-fluorouracil and folinic acid for liver metastases of colorectal cancer. German Cooperative on Liver Metastases (Arbeitsgruppe Lebermetastasen).** *Annals of surgery* 1998, **228**(6):756-762.
- Kemeny NE: **Regional chemotherapy of colorectal cancer.** *Eur J Cancer* 1995, **31A**(7-8):1271-1276.
- Vauthey JN, Marsh Rde W, Cendan JC, Chu NM, Copeland EM: **Arterial therapy of hepatic colorectal metastases.** *The British journal of surgery* 1996, **83**(4):447-455.
- Ludwig J, Kim CH, Wiesner RH, Krom RA: **Floxuridine-induced sclerosing cholangitis: an ischemic cholangiopathy?** *Hepatology (Baltimore, Md)* 1989, **9**(2):215-218.
- Bolton JS, Bowen JC: **Biliary sclerosis associated with hepatic artery infusion of floxuridine.** *Surgery* 1986, **99**(1):119-122.
- Jager D, Warzelhan J, Jager E, Knuth A: **[Penetrating duodenal ulcer as a complication of a hepatic artery port catheter in hepatic metastasis of sigmoid carcinoma].** *Med Klin (Munich)* 1997, **92**(11):680-682.
- Oberfield RA, McCaffrey JA, Polio J, Clouse ME, Hamilton T: **Prolonged and continuous percutaneous intra-arterial hepatic infusion chemotherapy in advanced metastatic liver adenocarcinoma from colorectal primary.** *Cancer* 1979, **44**(2):414-423.
- Roybal JJ, Feliberti EC, Rouse L, Wagman LD: **Pump removal in infected patients with hepatic chemotherapy pumps: when is it necessary?** *The American surgeon* 2006, **72**(10):880-884.
- Liu LX, Zhang WH, Jiang HC, Zhu AL, Wu LF, Qi SY, Piao DX: **Arterial chemotherapy of 5-fluorouracil and mitomycin C in the treatment of liver metastases of colorectal cancer.** *World J Gastroenterol* 2002, **8**(4):663-667.
- Tzoracoleftherakis E, Patrino V, Koukouras D: **Hepatic Artery Aneurysm Complicating Intra-arterial Chemotherapy for Hepatocellular Carcinoma.** *Hepato-Gastroenterology* 2003, **50**:830-831.
- Pross M, Ridwelski K, Reiher F, Lippert H: **Hepatic artery aneurysm associated with upper gastrointestinal bleeding after intrahepatic artery chemotherapy.** *Hepatogastroenterology* 1999, **46**(28):2285-2288.
- Noda M, Kusunoki M, Yanagai H, Yamamura T, Utsunomiya J: **Hepatic artery-biliary fistula during infusion chemotherapy.** *Hepatogastroenterology* 1996, **43**(11):1387-1389.

26. Rosenberg HD, Wile AG, Aufrichtig D, Armentrout SA: **Hepatic artery-biliary fistula. An unusual complication of infusion therapy.** *Gastrointestinal radiology* 1983, **8(1)**:37-40.
27. O'Driscoll D, Olliff SP, Olliff JF: **Hepatic artery aneurysm.** *The British journal of radiology* 1999, **72(862)**:1018-1025.
28. Shanley CJ, Shah NL, Messina LM: **Common splanchnic artery aneurysms: splenic, hepatic, and celiac.** *Annals of vascular surgery* 1996, **10(3)**:315-322.
29. Salam TA, Lumsden AB, Martin LG, Smith RB 3rd: **Nonoperative management of visceral aneurysms and pseudoaneurysms.** *American journal of surgery* 1992, **164(3)**:215-219.
30. Laopaiboon V, Aphinives C, Pongsuwan P, Pugnem A, Thammaroj J, Puttharuk W: **Hepatic artery embolization to control liver hemorrhages by interventional radiologists: experiences from Khon Kaen University.** *Journal of the Medical Association of Thailand = Chotmaihet thangphaet* 2006, **89(3)**:384-389.
31. Tulsyan N, Kashyap VS, Greenberg RK, Sarac TP, Clair DG, Pierce G, Ouriel K: **The endovascular management of visceral artery aneurysms and pseudoaneurysms.** *J Vasc Surg* 2007, **45(2)**:276-83; discussion 283.
32. Tsai CC, Chiu KC, Mo LR, Jao YT, Lin YW, Yang TM, Chang KK: **Transcatheter arterial coil embolization of iatrogenic pseudoaneurysms after hepatobiliary and pancreatic interventions.** *Hepatogastroenterology* 2007, **54(73)**:41-46.
33. Gabelmann A, Gorich J, Merkle EM: **Endovascular treatment of visceral artery aneurysms.** *J Endovasc Ther* 2002, **9(1)**:38-47.
34. Rossi M, Rebonato A, Greco L, Citone M, David V: **Endovascular exclusion of visceral artery aneurysms with stent-grafts: technique and long-term follow-up.** *Cardiovascular and interventional radiology* 2008, **31(1)**:36-42.
35. Larson RA, Solomon J, Carpenter JP: **Stent graft repair of visceral artery aneurysms.** *J Vasc Surg* 2002, **36(6)**:1260-1263.
36. Souftas VD, Prassopoulos P: **Computed-tomography-guided direct percutaneous transhepatic embolization of a bleeding hepatic artery branch aneurysm.** *Acta Radiol* 2006, **47(5)**:461-464.
37. Dambin C, Marcheix B, Birsan T, Cron C, Muscari F, Suc B, Cerene A, Rousseau H: **Posttraumatic pseudoaneurysm of the hepatic artery: treatment with ultrasound-guided percutaneous transhepatic thrombin injection.** *The Journal of trauma* 2005, **59(1)**:239-242.
38. Mocellin S, Pilati P, Lise M, Nitti D: **Meta-analysis of hepatic arterial infusion for unresectable liver metastases from colorectal cancer: the end of an era?** *J Clin Oncol* 2007, **25(35)**:5649-5654.
39. Campbell KA, Burns RC, Sitzmann JV, Lipsett PA, Grochow LB, Niederhuber JE: **Regional chemotherapy devices: effect of experience and anatomy on complications.** *J Clin Oncol* 1993, **11(5)**:822-826.

Publish with **BioMed Central** and every scientist can read your work free of charge

"BioMed Central will be the most significant development for disseminating the results of biomedical research in our lifetime."

Sir Paul Nurse, Cancer Research UK

Your research papers will be:

- available free of charge to the entire biomedical community
- peer reviewed and published immediately upon acceptance
- cited in PubMed and archived on PubMed Central
- yours — you keep the copyright

Submit your manuscript here:
http://www.biomedcentral.com/info/publishing_adv.asp

